

Benefit of extraperitonization to prevent septic intraabdominal complications after distal rectal cancer surgery

Boyko Atanasov,¹ Boris Sakakushev²

¹Surgical Unit, MHAT "Eurohospital" Plovdiv; ²General Surgery Department, Medical University Plovdiv, University Hospital St. George, Plovdiv, Bulgaria

Abstract

Colorectal cancer is one of the most common oncological diseases. Surgery is the main treatment modality and laparoscopic colorectal resection has been gaining popularity over the past two decades. Neo-adjuvant therapy is considered standard treatment for 2nd and 3rd stage distal rectal cancer. We present our retrospective study of 127 patients with anterior resection (ARR) and total mesorectal excision (TME) for low rectal cancer operated on between 2012 and 2015 in two surgical wards. In all 59 laparoscopic ARR neoadjuvant therapy, intra-abdominal drainage and ileostomy was performed, while extra-peritonization was done in 21 and no pre-sacral drainage was used. In the conventional group of 68 ARR, 21 had neo-adjuvant therapy, everyone has had extra-peritonization, pre-sacral drainage and no protective ileostomy performed. Early postoperative complications were registered in 25 patients, 24 related to the operation and 1 due to a recurrent brain stroke, all classified from I to III by Clavien Dindo scale. There were 9 anastomosis insufficiencies: 6 in conventional and 3 in laparoscopic operations. In 3 patients (2 conventional and 1 laparoscopic) with low ARR and signs of peritoneal contamination re-laparotomy was performed with successive outcome. All patients survived. Our routine practice of extra-peritonization and pre-sacral-perianal drainage in open ARR eliminate the possibility of postoperative peritonitis after anastomosis insufficiency, limiting the infection to low pelvic phlegmona and local intra-abdominal pelvic infection in overlooked cases.

Correspondence: Boris Sakakushev, General Surgery Department, Medical University Plovdiv, University Hospital St. George, Plovdiv, Bulgaria.
E-mail: bsakakushev@gmail.com

Key words: Rectum; distal rectal cancer; laparoscopic surgery; anastomotic leakage.

Received for publication: 25 March 2016.
Revision received: 17 October 2016.
Accepted for publication: 17 October 2016.

©Copyright B. Atanasov and B. Sakakushev, 2016
Licensee PAGEPress, Italy
Journal of Peritoneum (and other serosal surfaces) 2016; 1:7
doi:10.4081/joper.2016.7

This article is distributed under the terms of the Creative Commons Attribution Noncommercial License (by-nc 4.0) which permits any noncommercial use, distribution, and reproduction in any medium, provided the original author(s) and source are credited.

Introduction

Colorectal cancer is common oncological disease with high morbidity and mortality, where in complex treatment, surgery is of main importance. According to the national cancer registry of Bulgaria for 2012 new cases of rectal carcinoma were 1528. It is most common after 75 years of age. Distal rectal cancer operations are still a challenge, even for experienced surgeons, where laparoscopic approach is gaining popularity, and neo-adjuvant therapy is a standard for II-nd and III stage of the disease.^{1,2} Laparoscopic, compared to conventional operations have been advocated to have less complications,³ concerning the most common ones - surgical site infection (SSI), anastomosis leakage, post-operative ileus and bleeding, all assessed by Clavien-Dindo classification.⁴ Anastomosis insufficiency rate in colorectal surgery varies from 2 to 26%,^{5,6} being higher in low and ultralow rectum resections. Anastomosis leakage (takedown, disruption, insufficiency) is the feculent or gas discharge through and around the anastomosis in the abdominal cavity, pelvis, operative wound and *via* drains. The incidence of clinically significant leakage after low anterior resection varies between 3% and 21%, but is thought to average 10%, or lower, when patients are operated by a high-volume surgeon.^{7,8}

Risk factors for anastomosis leakage like male sex, advanced age, overweight, low rectal cancer (10 cm from ano-rectal line), 3 \geq Charlson index, high ligation of superior mesenteric artery, sepsis, neo-adjuvant chemotherapy, smoking, high American Society of Anesthesiologist (ASA) score, longer operative time (1.9), can be stratified by colon leakage score.^{9,10} Intraoperative anastomosis check, good blood supply, tension free and meticulous operative technique are pre-requisites for better anastomosis healing. Protective ileostomy in low anterior rectum resection (ARR) has more advocates than oponents.⁴

Materials and Methods

A total of 127 patients with low rectal cancer, operated on between 2012 and 2015 in the Surgical Unit of Mhat "Eurohospital" and Surgical Department of University Hospital St. George, Plovdiv, have been retrospectively analyzed. Males were 62.2% (n=79), females - 37.8% (n=48) (Figure 1).

In all 59 low and ultralow laparoscopic ARR, neo-adjuvant therapy, intra-abdominal drainage and ileostomy was performed, while extra-peritonization was done in 21 and no pre-sacral drainage was used. In the conventional group of 68 ARR, 21 had neo-adjuvant therapy, everyone have had extra-peritonization, pre-sacral and intra-abdominal drainage and no protective ileostomy performed. We routinely apply extra-peritonization and pre-sacral-perianal tube drainage in open ARR (Table 1).

Results

Early postoperative complications were registered in 25 patients, 24 related to the operation and 1 due to a recurrent brain stroke, all classified from I to III by Clavien Dindo scale from 2009 (Figure 2).

The Laparoscopic group did not show any intraoperative complications, while postoperative ones were in 9 subjects. From 127 cases of low and ultralow ARR performed both laparoscopically and conventionally there were 9 anastomosis insufficiencies - 6 in conventional and 3 in laparoscopic operations. Two leakages after open procedures were partial, recognized as stapler misfits, after firing and were over-sutured manually intra-operatively. The first case went uneventfully and leaved the ward 6 days later. The second one developed low pelvic abscess and fistula, postoperative anastomosis stricture, partially resolved by dilations and strictureplasty in the following 18 months with satisfactory outcome. In 4 patients conservative treatment (drainage and antibiotics) was successful. In 3 patients (2 conventional and 1 laparoscopic) with signs of peritoneal contamination re-laparotomy was performed.

Anastomosis take down (more than 1/2 of the circumference) with fibrinous purulent peritonitis, originating from low pelvis phlegmona was found, requiring Hartmann's obstructive colon resection and stoma. SSI have been registered in 7 cases with isolates of *Escherichia coli*, *Enterococcus fecalis* and *Pseudomonas aeruginosa*. Postoperative ileus in 7 patients was dealt with conservatively and only 1 case required re-laparotomy for debridement. Postoperative bleeding after Miles operation was successfully managed by perianal wound tamponade. All patients survived (lethality=0).

Discussion

Colorectal cancer rate is currently raising, intending to become a leader in cancer mortality. Surgery remains the crucial method of treatment and laparoscopic approach is gaining popularity in Asia and part of Europe. Distal II and III staged rectal cancers require neo-adjuvant therapy. We have considered all (59) laparoscopic ARR as high risked for anastomosis insufficiency, due to advanced stage (II and III), neo-adjuvant chemotherapy and distal rectal localization and therefore we have performed protective ileostomy. Consequently we recommend this procedure as appropriate preventive measure in high-risk patients.^{11,12} Our postoperative complication rates related to surgery of 13.33% (n=24) and anastomosis insufficiency rate of 5% (n=9) are comparable with the reported ones of 2-26%.^{5,6} For early diagnosis of anastomosis leakage we use ultrasonography, X-ray, computed tomography (CT), endoscopy, considering CT the most relevant one.¹³

Our routine practice of extra-peritonization the anastomosis and pre-sacral-perianal drainage usually with 1 or 2 tube drains eliminate the possibility of spreading the infection and fecal leakage intra-abdominally, after ARR anastomosis insufficiency, limiting the infection to low pelvic phlegmona and/or local intra-abdominal pelvic infection in overlooked cases. Late complications are perianal fistula or anastomosis stricture, which are dealt with satisfactory outcome.

The use of both extra-peritonization and pre-sacral drainage in conventional low and ultralow ARR has been a routine procedure applied for decades in our clinic, with proven efficiency and effectiveness in anastomosis insufficiency. The restoration of the surgical anatomy in the low pelvis by extra-peritonization avoids slipping down of small bowel loops causing bowel obstruction. It saves the life of the patient in potential or accidental anastomosis dehiscence, transforming diffuse stercoral peritonitis into a well-drained (by pre-sacral drainage) low pelvis phlegmona.

In small (partial) anastomosis insufficiency extra-peritonization

and pre-sacral drainage enhances local control of low pelvis infection, limiting stercoral secretion, potentiating granulation and recto-atmospheric fistula channel formation, controlled through the pre-sacral drainage route. Thus we avoid re-operation in acute stage and treat the fistula usually by elastic Seaton at a later stage. In post-operative intra-abdominal hemorrhage, due to vessel suture (clip) takedown, the hemoperitoneum or intra-intestinal abscess does not affect the extra-peritonized anastomosis, requiring its revision.

Table 1. Types and techniques of operations.

	Conventional	Laparoscopic
ARR with TME	68	59
Neo-adjuvant therapy	21	59
Extraperitonization	68	21
Pre-sacral drainage	68	0
Intra-abdominal drainage	68	59
Protective ileostomy	0	59

ARR, anterior rectum resection; TME, total mesorectal excision.

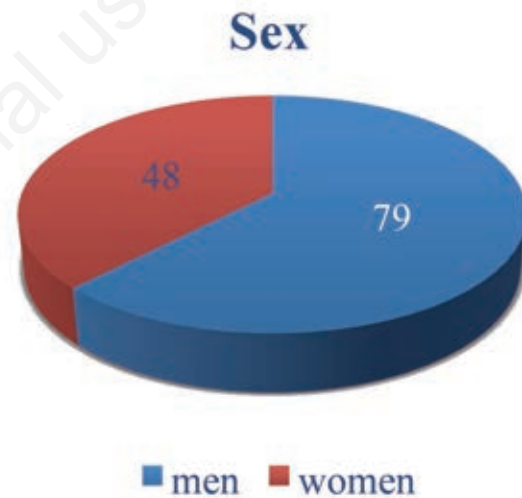


Figure 1. Male/female ratio.

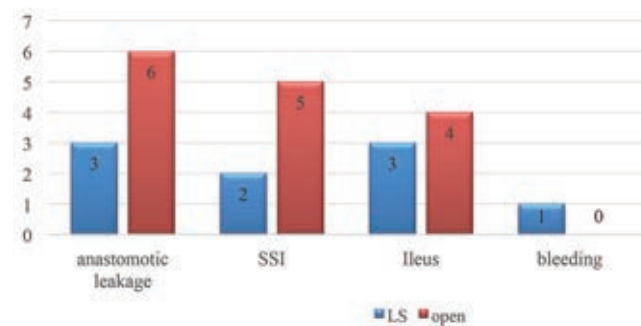


Figure 2. Postoperative complications. SSI, surgical site infection; LS, laparoscopic.

Extra-peritonisation of the anastomosis and pre-sacral drainage allow conservative control in more than half of the patients with anastomosis insufficiency. Following an algorithm approach results in overcoming this complication and saves sphincter function.

Conclusions

The absolute number of patients with ARR will grow because of increasing rate of colo-rectal cancer, life length and growing requirements (increasing rate of sphincter saving operations).

Despite improvements in proficiency of surgical technique, anastomotic leakage after colorectal cancer surgery continues to be a major clinical problem.¹⁴ Surgery for distal rectal cancer independently of high progress in medicine is still a challenge even for colo-proctologists.

References

1. Sauer R, Becker H, Hohenberger W, et al. Preoperative versus postoperative hemoradiotherapy for rectal cancer. *N Engl J Med* 2004;351:1731-40.
2. Tepper JE, O'Connell MJ, Petroni GR, et al. Adjuvant postoperative fluorouracil-modulated chemotherapy combined with pelvic radiation therapy for rectal cancer: initial results of intergroup 0114. *J Clin Oncol* 1997;15:2030-9.
3. Luglio G, De Palma GD, Tarquini R, et al. Laparoscopic colorectal surgery in learning curve: role of implementation of a standardized technique and recovery protocol. A cohort study. *Annals Med Surg* 2015;4:89-94.
4. Clavien PA, Barkun J, de Oliveira ML, et al. The Clavien-Dindo classification of surgical complications: five-year experience. *Ann Surg* 2009;250:187-96.
5. Boccola MA, Buettner PG, Rozen WM, et al. Risk factors and outcomes for anastomotic leakage in colorectal surgery: a single-institution analysis of 1576 patients. *World J Surg* 2011;35:186-95.
6. Fouda E, El Nakeeb A, Magdy A, et al. Early detection of anastomotic leakage after elective low anterior resection. *J Gastrointest Surg* 2011;15:137-44.
7. Taflampas P, Christodoulakis M, Tsiftsis D. Anastomotic leakage after low anterior resection for rectal cancer: facts, obscurity, and fiction. *Surg Today* 2009;39:183-8.
8. Komen N, Dijk J, Lalmahomed Z. After-hours colorectal surgery: a risk factor for anastomotic leakage. *Int J Colorectal Dis* 2009;24:789-95.
9. Dekker JW, Liefers GJ, de Mol van Otterloo JC, et al. Predicting the risk of anastomotic leakage in left-sided colorectal surgery using a colon leakage score. *J Surg Res* 2011;166:e27-34.
10. Trencheva K, Morrissey K, Wells M, et al. Identifying important predictors for anastomotic leak after colon and rectal resection prospective study on 616 patients. *Ann Surg* 2013;257:108-13.
11. Nachiappan S, Askari A, Currie A, et al. Intraoperative assessment of colorectal anastomotic integrity: a systematic review. *Surg Endosc* 2014;28:2513-30.
12. Yang L, Huang X, Zhou J, et al. Risk assessment on anastomotic leakage after rectal cancer surgery: an analysis of 753 patients. *Asian Pacif J Cancer Prev* 2013;14:4448-51.
13. Daams F, Luyer M, Lange JF. Colorectal anastomotic leakage: aspects of prevention, detection and treatment. *World J Gastroenterol* 2013;19:2293-7.
14. Sakakushev B, Hadzhiev B, Boev B, et al. Colorectal anastomotic leak - unexpected fatal disaster or a predictable controlled probability? A 2009 update. *Scripta Sci Med* 2009;41:219-24.